

Thermal Burns Caused by Warming Blankets in the Operating Room

MARJANNE H. CRINO, M.D.^{*}, AND EUGENE L. NAGEL, M.D.[†]

Two cases are presented to direct attention to circumstances in which thermal burns can occur with use of warming blankets which are not defective and which are operating within "safe" temperature limits.

CASE 1

A 63-year-old white man weighing 187 pounds was admitted with the diagnosis of bilateral iliac artery occlusion, arteriosclerotic heart disease, and diabetes mellitus. A warming blanket was placed on the operating room table, under the patient's hips and lower back, because of the anticipated prolonged surgical time. This blanket was covered by a double layer of drape sheet and the blanket's temperature regulator was set at 100° F. The patient underwent an aorto-bifemoral bypass with dacron graft placement and uneventful general anesthesia. The total time for the procedure was six hours and 15 minutes. After several hours in the recovery area, the patient was returned to the operating room for further surgery. This procedure required an additional hour and 45 minutes. The postoperative course was then uncomplicated until the second postoperative day when the patient began to complain of severe discomfort in the sacral area. On examination he was found to have an area of burn over the sacrum estimated to be 40 per cent third-degree, 60 per

cent second-degree, with strips of second degree burn extending over the buttocks. The area of burn corresponded to the location of the warming blanket used during surgery and the pattern of burn to the fluid channels in the coils of the warming blanket (fig. 1).

CASE 2

A 67-year-old white woman weighing about 150 pounds was admitted with gangrene of the right great toe and diabetes mellitus. After attempts to control the diabetes, she underwent an aorto-femoral bypass graft under general anesthesia. A warming blanket covered by a sheet was placed under the patient's shoulders and midback. The total operating time was seven hours and 15 minutes. On the second postoperative day the patient complained of "soreness" over her upper back. Examination revealed several areas of second-degree burn in a symmetrical pattern over the midthoracic area. Linear areas of erythema extended along the back and corresponded in spacing to the fluid channels in the warming blanket.

DISCUSSION

In both cases the most severe injury occurred in areas of greatest pressure, namely, over bony prominences. Both patients were diabetic, moderately obese, and had some degree of vascular insufficiency. Preparative solutions used for skin cleansing may have predisposed to this injury. The pattern of burn in each case corresponded exactly to the

Formerly Instructor, Department of Anesthesiology, University of Miami School of Medicine and Jackson Memorial Hospital, Miami, Florida. Present address: 171 Rutgers St., Rochester, N. Y.

† Assistant Professor, Department of Anesthesiology, University of Miami School of Medicine and Jackson Memorial Hospital, Miami, Florida.

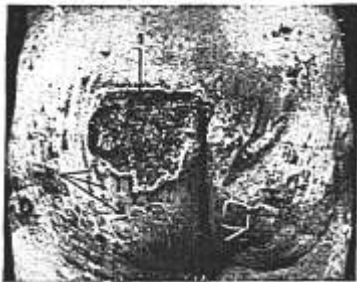


FIG. 1. (1) Area of third degree burn, left sacrum; (2) burns corresponding to ridges of thermal blanket.

area of contact and to the fluid channel spacing in the warming blanket.

Following these two incidents, four thermal blankets and accompanying control units were calibrated using a laboratory thermometer as a standard. All four units were found to be within manufacturer's tolerances which allow approximately 9 degrees F. differential between the control unit reservoir and the blanket surface temperature. In most temperature-control equipment designed for patient use, the maximum blanket temperature recommended is 105 degrees F. However, this manufacturer suggested a lower temperature

setting for patients having vascular insufficiency or diabetes and for infants. Recalibration of control units was recommended following impact or other mechanical abuse. Regardless of individual manufacturer's instructions, guidelines are not well established concerning variables such as length of procedure, patient weight, patient position, condition of patient (*e.g.*, diabetes, vascular insufficiency, etc.), patient age (infant), and temperature at the blanket-patient interface. Scott¹ presented three cases in which significant skin injury occurred following use of a thermal blanket during open heart surgery. He felt that the injury might have been compounded by pressure necrosis, because the areas involved were over bony prominences. In one case an electrocoagulating grounding plate was noted to have been in contact with the skin at the site of injury and may have acted as a heat conductor, thereby contributing to the injury.

It is concluded that for certain patients a lower temperature setting should be used, depending upon length of procedure, position, patient condition, and other factors. These limits have not yet been determined.

REFERENCE

1. Scott, S. M.: Thermal blanket injury in the operating room, *Arch. Surg.* 94: 181, 1967.